

Circulation

JOURNAL OF THE AMERICAN HEART ASSOCIATION



Torsades de pointes: electrophysiologic studies in patients without transient pharmacologic or metabolic abnormalities

LN Horowitz, AM Greenspan, SR Spielman and ME Josephson

Circulation 1981;63:1120-1128

Circulation is published by the American Heart Association, 7272 Greenville Avenue, Dallas, TX 72514

Copyright © 1981 American Heart Association. All rights reserved. Print ISSN: 0009-7322. Online ISSN: 1524-4539

The online version of this article, along with updated information and services, is located on the World Wide Web at:

<http://circ.ahajournals.org>

Subscriptions: Information about subscribing to *Circulation* is online at
<http://circ.ahajournals.org/subscriptions/>

Permissions: Permissions & Rights Desk, Lippincott Williams & Wilkins, a division of Wolters Kluwer Health, 351 West Camden Street, Baltimore, MD 21202-2436. Phone: 410-528-4050. Fax: 410-528-8550. E-mail:
journalpermissions@lww.com

Reprints: Information about reprints can be found online at
<http://www.lww.com/reprints>

- Academic Press, 1972, pp 299-340
16. Clarkson PM, Gomez MR, Wallace RB, Weidman WH: Central nervous system complications following Blalock-Taussig operation. *Pediatrics* **39**: 18, 1967
17. Bada HS, Hajjar W, Chua C, Sumner DS: Noninvasive

- diagnosis of neonatal asphyxia and intraventricular hemorrhage by Doppler ultrasound. *J Pediatr* **95**: 775, 1979
18. Lou HC, Lassen NA, Friis-Hansen B: Impaired autoregulation of cerebral blood flow in the distressed newborn infant. *J Pediatr* **94**: 118, 1979

Torsades de Pointes: Electrophysiologic Studies in Patients Without Transient Pharmacologic or Metabolic Abnormalities

LEONARD N. HOROWITZ, M.D., ALLAN M. GREENSPAN, M.D., SCOTT R. SPIELMAN, M.D.,
AND MARK E. JOSEPHSON, M.D.

SUMMARY Electrophysiologic studies were performed in 21 patients who had torsades de pointes. This ventricular tachyarrhythmia, characterized by rapid (200–250 beats/min) and irregular paroxysms and progressively varying QRS amplitude and polarity, occurred in the absence of electrolyte disturbance, antiarrhythmic drug therapy or acute ischemia. The QT_c interval was prolonged in seven of 21 patients. Electrophysiologic study included ventricular pacing with the introduction of one to three extrastimuli and rapid ventricular pacing. The effect of i.v. procainamide or quinidine in these patients was also studied. Torsades de pointes was inducible in 19 of 21 patients. Induced episodes closely resembled spontaneous episodes. Torsades de pointes spontaneously progressed to ventricular tachycardia with a uniform morphology in three patients and to ventricular fibrillation in four. In eight patients, procainamide or quinidine converted torsades de pointes into typical reentrant ventricular tachycardia. Our data suggest that torsades de pointes in this setting may be a rapid reentrant ventricular tachycardia closely related to recurrent sustained ventricular tachycardia and a precursor to ventricular fibrillation and sudden death.

IN 1966, Dessertenne applied the term torsades de pointes to a distinctive ventricular tachyarrhythmia. Examples of this arrhythmia had been published under a variety of names over the preceding 50 years.¹⁻⁶ It is characterized by paroxysms of ventricular tachycardia at rates typically greater than 200 beats/min in which the QRS morphology shows alternating polarity in an undulating pattern so that the complexes appear to be twisting about the baseline; hence the name torsades de pointes — “twisting of the points” (fig. 1). The designation of this arrhythmia by a specific title suggests that it is a specific electro-

physiologic and clinical entity because of its etiologic and therapeutic peculiarities. Although it frequently occurs in the setting of a prolonged QT interval due to hypokalemia or antiarrhythmic drugs, it can also occur without these transient abnormalities.⁷⁻¹³ In the present study we investigated the electrophysiologic characteristics of this arrhythmia in patients without transient precipitating factors.

Patients

The study population included 21 patients, 13 males and eight females, ages 30–72 years, in whom torsades de pointes¹⁴ was induced during electrophysiologic studies or occurred spontaneously (table 1). All but two patients had had at least three spontaneous episodes of torsades de pointes documented electrocardiographically, either by computer-monitored continuous electrocardiographic recording in a coronary care unit or Holter monitoring during observation periods of 4–13 days. The two patients in whom torsades de pointes occurred only during electrophysiologic studies had frequent multiform premature ventricular depolarizations and nonsustained ventricular tachycardia, and thus did not fulfill strict criteria for the diagnosis of torsades de pointes. Eleven patients had suffered cardiac arrest, with ventricular tachycardia or fibrillation documented as the mechanism.

Torsades de pointes always occurred in the absence

From the Electrophysiology Laboratory, Hospital of the University of Pennsylvania, and the Cardiovascular Section, Department of Medicine, University of Pennsylvania School of Medicine, Philadelphia, Pennsylvania.

Dr. Horowitz is recipient of Young Investigator Award R23 HL21292, NHLBI.

Dr. Greenspan is the recipient of Special Investigatorship Award 1979–1981, American Heart Association, Southeastern Pennsylvania Chapter.

Dr. Josephson is the recipient of Research Career Development Award K04 HL00361, NHLBI.

Supported in part by grants from the American Heart Association, Southeastern Pennsylvania Chapter, and the NHLBI.

Address for correspondence: Leonard N. Horowitz, M.D., Electrophysiology Laboratory, Hospital of the University of Pennsylvania, 3400 Spruce Street, Philadelphia, Pennsylvania 19104.

Received June 18, 1980; revision accepted September 3, 1980.

Circulation **63**, No. 5, 1981.

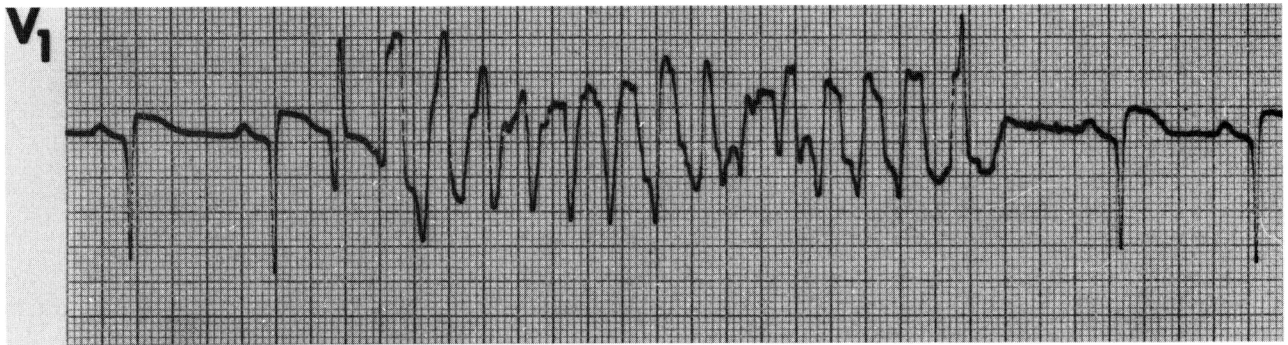


FIGURE 1. Spontaneous paroxysm of torsades de pointes in patient 2. A V_1 rhythm strip is shown. A single premature depolarization after the second sinus complex initiated a typical paroxysm of torsades de pointes.

of bradyarrhythmias, antiarrhythmic or digitalis therapy, electrolyte imbalance, and recent (less than 4 weeks) myocardial infarction. For this analysis we have excluded patients in whom torsades de pointes was observed only during transient abnormalities of rhythm, metabolic state or therapy with agents that have been reported to induce this arrhythmia.

The cardiac diagnoses and other demographic data are presented in table 1. The QT/QT_c intervals were measured during sinus rhythm when the patients were having spontaneous episodes.^{15, 16} With the Bazett method,¹⁵ 14 patients had normal QT_c intervals and seven had minimally prolonged QT_c intervals (greater than 0.392 for males and greater than 0.44 for fe-

TABLE 1. Demographic Data

Pt.	Age (years)	Sex	Diagnosis	ECG morphology	QT/QT_c (sec)	Clinical arrhythmia	Number of complexes in paroxysms of torsades de pointes
1	61	F	CAD, Vent. an.	AMI, IMI	0.37/0.37	TdP, VF	6-26
2	44	M	CAD, Vent. an.	AMI	0.37/0.40	TdP	6-12
3	52	M	CAD, Vent. an.	AMI, LAHB	0.32/0.42	VPDs	15-23
4	51	M	AS, CAD	AMI, LVH	0.31/0.37	TdP, VF	6->100
5	44	M	CAD, Vent. an.	AMI	0.35/0.38	TdP, VF	9-24
6	51	M	CAD	WNL	0.38/0.38	TdP, VF	12-19
7	59	F	CM	WNL	0.38/0.42	TdP	23-31
8	62	M	CAD	IMI	0.37/0.39	TdP, VF	15-30
9	50	M	CAD	IMI, AMI	0.42/0.38	VPDs	12-30
10	44	F	CM	WNL	0.38/0.39	TdP	9-13
11	55	M	CM	NSSTTWA	0.39/0.30	TdP	6-34
12	57	F	CM	WNL	0.29/0.40	TdP, VF	6-21
13	51	M	RHD	LVH, AF	0.28/0.31	TdP	15-23
14	52	M	CAD	IMI	0.40/0.39	TdP, VF	7-18
15	67	M	PEHD	WNL	0.39/0.41	TdP, VF	11-37
16	59	F	HTN	LBBB	0.42/0.42	TdP	10-17
17	72	F	CAD	LBBB	0.36/0.42	TdP	8-11
18	68	M	CAD, Vent. an.	AMI	0.38/0.40	TdP, VF	7-27
19	56	M	CAD, Vent. an.	AMI, IMI	0.31/0.37	TdP	8-17
20	35	F	MVP	NSSTTWA	0.42/0.46	TdP, VF	7-28
21	55	F	CAD	AMI, IMI	0.45/0.51	TdP, VF	12-34

Abbreviations: AF = atrial fibrillation; AMI = anterior myocardial infarction; AS = aortic stenosis; CAD = coronary artery disease; CM = cardiomyopathy; HTN = hypertension; IMI = inferior myocardial infarction; LAHB = left anterior hemiblock; LBBB = left bundle branch block; LVH = left ventricular hypertrophy; MVP = mitral valve prolapse; NSSTTWA = nonspecific ST- and T-wave abnormalities; PEHD = primary electrical heart disease; QT_c = measured in control state by Bazett's method; RHD = rheumatic heart disease; RV = right ventricle; TdP = torsades de pointes; Vent. an. = ventricular aneurysm; VF = ventricular fibrillation; VPD = ventricular premature depolarization; WNL = within normal limits.

males). With the newer method of Simonson et al.,¹⁶ two patients had prolonged QT intervals corrected for rate. No patient had a QT_c interval greater than 0.51 second. Atrial pacing did not cause an increase in QT or QT_c in any patient.

Methods

All patients were referred specifically for evaluation of ventricular tachycardia or syncope. The diagnosis of torsades de pointes was made using the electrocardiographic criteria suggested by Dessertenne,¹ Slama et al.,^{7, 11} Krikler and Curry¹² and the WHO/ISFS Task Force.¹⁴ These criteria include (1) paroxysms of ventricular tachycardia, during which the rhythm is irregular and usually has an average rate of 200–250 beats/min; (2) progressive changes in amplitude and polarity of the QRS complexes, usually in an interval of five to 10 complexes such that the QRS axis changes and the complexes appear to be twisting around the isoelectric baseline; (3) spontaneous termination after a few complexes or as long as several minutes and consecutive episodes that vary widely in morphology and duration (fig. 1), (4) occasional progression of the arrhythmia to sustained uniform morphology ventricular tachycardia or ventricular fibrillation. We chose six complexes as the minimum number of complexes to define torsades de pointes.

Electrophysiologic studies were performed in the postabsorptive state after written informed consent had been obtained. All antiarrhythmic agents had been discontinued for more than five half-lives before study and plasma concentrations at the time of the study were below the measurable level by routine laboratory methods. Clinical status was stable and electrolyte measurements were normal and stable. Two to four electrode catheters were inserted percutaneously or by cutdown and positioned in the heart under fluoroscopic guidance. In each patient, catheters were positioned in at least one atrial site, usually the high right atrium, the His bundle position and the right ventricular apex. In selected patients, catheters were positioned in the right ventricular outflow tract (six patients) or left ventricle (seven patients) or both (five patients). Left ventricular electrograms were recorded in 18 of 21 patients, either from a left ventricular or coronary sinus catheter. Standard quadrapolar electrode catheters were used when recording and pacing from the same site were required. Stimulation was performed using a specially designed programmable stimulator and optically isolated constant current sources (Bloom Associates, Ltd.). The stimuli were rectangular pulses 1 msec in duration delivered at twice diastolic threshold (0.5–2.5 mA). Leakage current was regularly monitored and never exceeded 6 μ A.

The protocol of programmed stimulation included: atrial pacing at incremental rates (100–250 beats/min), premature atrial stimulation during sinus rhythm and/or atrial pacing, ventricular pacing at incremental rates (100–250 beats/min), or premature

ventricular stimulation during sinus rhythm and/or ventricular pacing. Single, double and triple extrastimuli were used. Diastole was scanned with the first premature stimulus (S₂) in 10–20-msec decrements until ventricular refractoriness. If no ventricular arrhythmia was initiated, the first premature stimulus (S₂) was introduced at a coupling interval (S₁S₂) 50–100 msec longer than the ventricular effective refractory period. A second premature stimulus (S₃) was introduced at an interval (S₂S₃) equal to S₁S₂. S₂S₃ was shortened by 10–20 msec until S₃ failed to capture the ventricle or initiate the arrhythmia. The S₁S₂ was then decreased until S₃ again captured the ventricle. The S₂S₃ was then shortened again. This procedure was continued until both S₂ and S₃ reached refractoriness. If no ventricular arrhythmia was initiated, a third premature stimulus was introduced at an interval (S₃S₄) equal to S₁S₂. The S₁S₂ was again programmed to 50–100 msec greater than the ventricular effective refractory period and S₂S₃ and S₃S₄, which were initially equal to S₁S₂, were decreased sequentially until S₂, S₃ and S₄ did not produce an evoked response. Stimulation was performed at two or more cycle lengths in 19 patients and at the right ventricular apex in all patients. Stimulation was also performed at the right ventricular outflow tract in six patients and in the left ventricle in seven patients if the arrhythmia was not initiated by pacing at the right ventricular apex. If sustained ventricular tachycardia was initiated, single, double and triple extrastimuli or rapid ventricular pacing (200–300 beats/min) was used in an attempt to terminate the arrhythmia.

Immediately after baseline studies, in which torsades de pointes was initiated at least three times, procainamide (1–2 g; 50 mg/min) or quinidine (600–1200 mg; 20 mg/min) was infused intravenously and programmed stimulation was repeated after the infusion.

Intracardiac recordings were filtered at 30–500 Hz and displayed simultaneously with two or three electrocardiographic leads and 10-msec time lines on an oscillographic recorder (Electronics for Medicine VR16). All data were stored on magnetic analog tape and later retrieved on photographic paper at speeds of 75–200 mm/sec.

Results

Initiation of Torsades de Pointes

Torsades de pointes was initiated by programmed ventricular stimulation in 19 of the 21 patients during control studies in the absence of antiarrhythmic drugs. The arrhythmia was initiated during both sinus rhythm and ventricular pacing in two patients and during ventricular pacing only in 17 patients (fig. 2). Initiation was accomplished by a single extrastimulus in two patients and required double extrastimuli in 17. Left ventricular stimulation was necessary in one patient. Rapid ventricular pacing also induced torsades de pointes in two of the 19 patients. In all 19 patients, initiation was reproducible; it was ac-

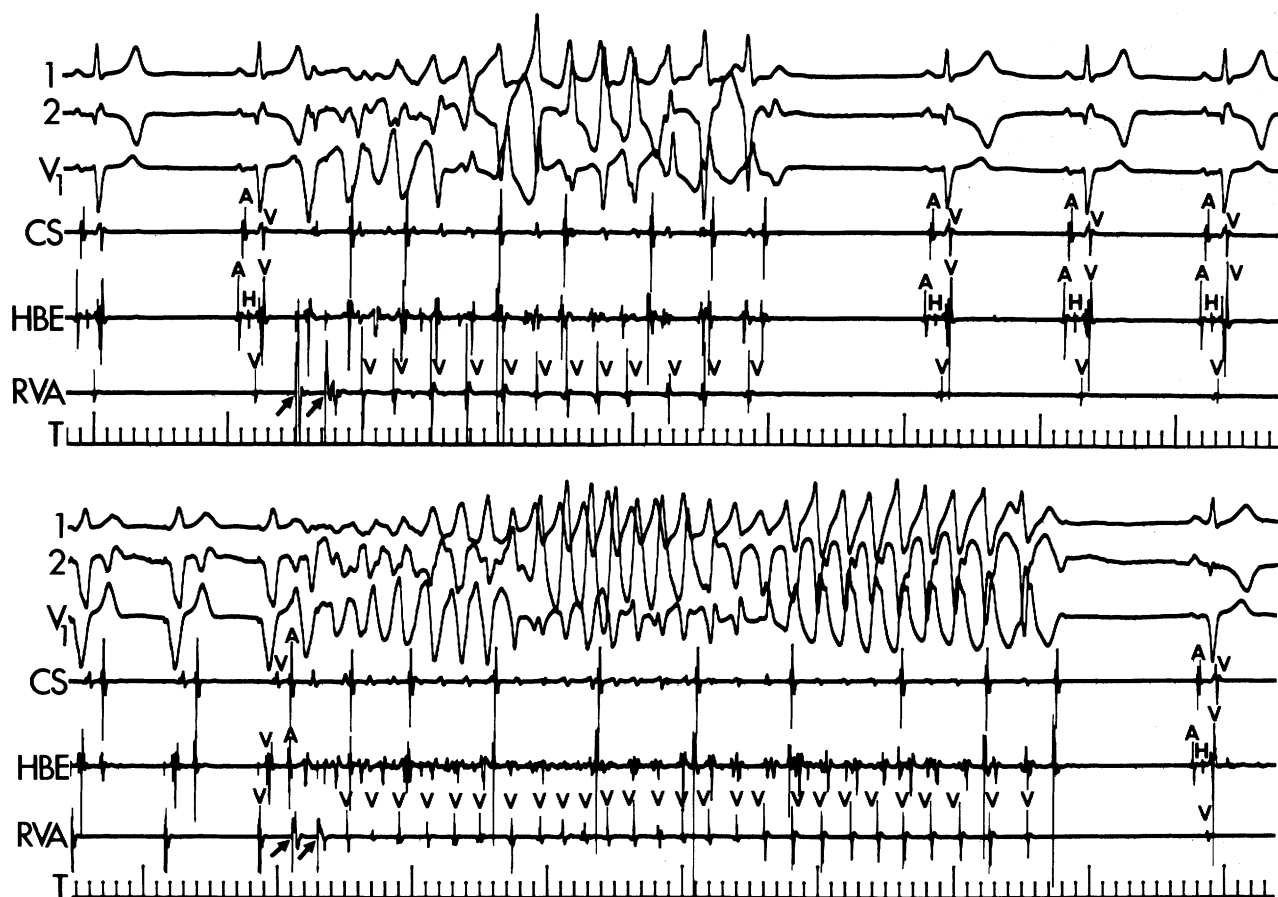


FIGURE 2. Initiation of torsades de pointes during normal sinus rhythm and ventricular pacing in patient 9. ECG leads 1, 2 and V_1 are shown with electrograms recorded in the coronary sinus (CS), His bundle area (HBE) and right ventricular apex (RVA) with 100-msec time marks (T). (top panel) Two premature stimuli (arrows) were introduced after the second sinus complex and a paroxysm of torsades de pointes was initiated. (bottom panel) Two premature stimuli (arrows) delivered after the third paced complex initiated a typical episode of torsades de pointes, which terminated spontaneously.

completed at least three times in each patient and over 10 times in 12 patients. Double extrastimuli were required for initiation in most patients, so the relationship between prematurity of the initiating stimulus and the interval to the first complex of torsades de pointes could not be assessed adequately.

In patients 7 and 21, in whom torsades de pointes occurred spontaneously, the arrhythmia could not be initiated by programmed stimulation. In these patients, single, double and triple extrastimuli introduced during sinus rhythm and ventricular pacing at two cycle lengths and rapid ventricular pacing were performed at the right ventricular apex, right ventricular outflow tract and at least two left ventricular sites. No clinical or electrophysiologic measurements distinguished these two patients from the 19 patients in whom torsades de pointes was inducible.

Observations During Torsades de Pointes

The QRS morphology during the induced paroxysms of torsades de pointes showed the typical undulating pattern of the spontaneous episodes. The duration, rate and electrocardiographic patterns of the induced episodes were not different from those of the

spontaneous ones (compare figures 1 and 2). The self-terminating paroxysms of induced torsades de pointes lasted a minimum of six complexes and a maximum of 34 complexes. The mean duration of these paroxysms was 17 ± 12 complexes. The duration and morphology of episodes varied widely in each patient during consecutive initiations. Paroxysms of torsades de pointes initiated during normal sinus rhythm tended to be shorter and have a longer mean cycle length than those initiated during ventricular pacing (fig. 2). Similarly, consecutive spontaneous episodes varied widely in duration and morphology.

The RR intervals and interelectrogram intervals measured at the site of stimulation varied widely during sequential paroxysms in individual patients. The shortest interelectrogram interval in the group was 110 msec and the longest was 360 msec. During individual paroxysms, the difference between the shortest and longest interelectrogram interval varied from 50–220 msec. The mean interelectrogram interval for all paroxysms in this group was 258 ± 87 msec. Although the interelectrogram intervals tended to lengthen and shorten sequentially in an oscillatory pattern, no specific pattern of oscillation was iden-

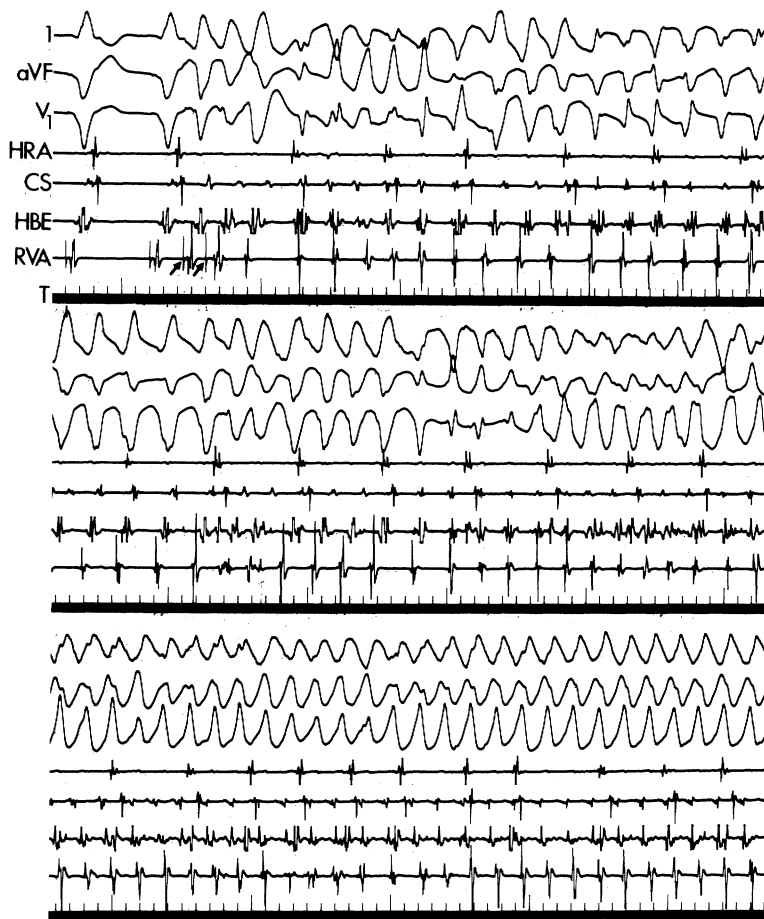


FIGURE 3. Spontaneous transition of torsades de pointes into ventricular tachycardia with a uniform QRS morphology in patient 4. In each of these three continuous panels, ECG leads I, aV_F and V₁ are shown with electrograms recorded in the high right atrium (HRA), coronary sinus (CS), His bundle area (HBE) and right ventricular apex (RVA), with 100-msec time lines (T). (top panel) During ventricular pacing, two premature stimuli were introduced (arrows) and a typical paroxysm of torsades de pointes was initiated. The paroxysm was sustained. (bottom panel) The paroxysm stabilized into a ventricular tachycardia with a uniform morphology.

tified for the group as a whole. Similar data were obtained by measuring intervals at other ventricular sites.

The activation sequence of ventricular electrograms varied continuously during episodes of torsades de pointes (figs. 2 and 3). As the QRS morphology changed from complex to complex, coincident changes in the relationship between the ventricular electrograms in the right and left ventricles were observed.

Termination of Torsades de Pointes

One hundred forty-eight of 155 episodes of torsades de pointes initiated in these patients terminated spontaneously. In 97 of 148 episodes, termination occurred after a sequence of three to five complexes showing progressively increasing interelectrogram intervals (fig. 2, bottom panel). In 22 episodes, spontaneous termination followed acceleration of the local electrograms and in 29, no specific pattern of interelectrogram intervals appeared. All episodes of torsades de pointes were too short to attempt termination by programmed stimulation.

Spontaneous Conversion of Torsades de Pointes to Sustained Ventricular Tachyarrhythmia

In four of 155 episodes (three patients), torsades de pointes progressed to sustained ventricular fibrillation,

which was terminated by countershock. In these patients (patients 5, 15 and 20), cardiac arrest due to electrocardiographically documented ventricular fibrillation had occurred before study. Except for degeneration to ventricular fibrillation, the characteristics (e.g., rate, RR interval variability) of these episodes were not significantly different from those that terminated spontaneously.

In three of 155 episodes (three patients), torsades de pointes organized into a sustained ventricular tachycardia of uniform morphology or ventricular flutter (fig. 3). The cycle lengths of these tachycardias were 170, 190 and 205 msec. When the uniform morphology developed, the activation pattern observed in the ventricular electrograms became constant. Each of these ventricular tachycardias required DC cardioversion because they rapidly produced hemodynamic deterioration.

Response to Procainamide or Quinidine

In eight patients the stimulation protocol that produced torsades de pointes during control studies initiated a sustained ventricular tachycardia with a uniform morphology after administration of procainamide (five patients) or quinidine (three patients) (fig. 4). The cycle length of these tachycardias ranged from 250–420 msec and had electrophysiologic

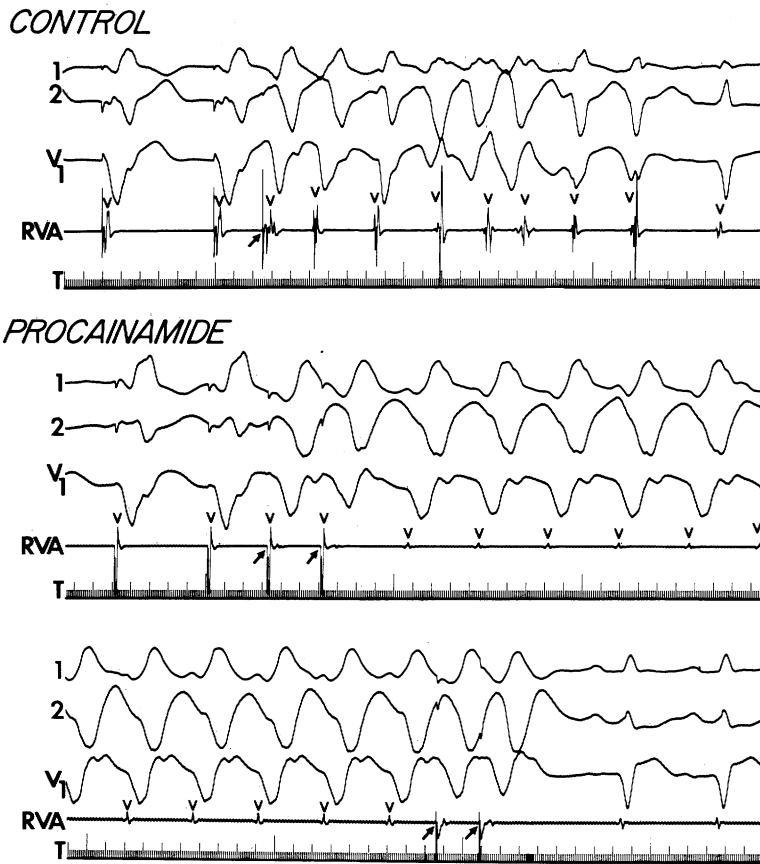


FIGURE 4. Conversion of torsades de pointes to sustained ventricular tachycardia by procainamide in patient 18. ECG leads 1, 2 and V_1 are shown, with electrograms recorded in the right ventricular apex (RVA) and 10-msec time lines (T). In the control panel, a single premature stimulus (arrow) initiated a spontaneously terminating paroxysm of torsades de pointes. No other ventricular arrhythmia could be initiated by programmed stimulation (single or double extrastimuli) in the control state. After 1500 mg of procainamide, which produced a blood level of 12.8 mg/l, sustained ventricular tachycardia with a uniform, stable morphology was initiated with two premature stimuli (arrows). The ventricular tachycardia was terminated by double extrastimuli (bottom panel, arrows).

characteristics identical to those described for recurrent sustained ventricular tachycardia.^{17, 18} In six patients, this tachycardia could be terminated by programmed extrastimuli (four patients) or rapid ventricular pacing (two patients) (fig. 4). Termination required cardioversion in the two remaining patients. Torsades de pointes was the only inducible ventricular arrhythmia during the control studies. In none was sustained ventricular tachycardia with uniform morphology inducible before procainamide or quinidine.

In two of the eight patients, ventricular tachycardia or torsades de pointes was inducible or occurred spontaneously during treatment with all standard antiarrhythmic drugs. In these two patients, surgery was performed for ablation of arrhythmias using intraoperative mapping to localize the site of origin.¹⁹ The surgery was performed during treatment with procainamide to maintain a uniform-morphology ventricular tachycardia. In each, the site of origin was identified and resected. In neither patient was torsades de pointes or sustained uniform-morphology ventricular tachycardia inducible by programmed electrical stimulation postoperatively, nor have spontaneous episodes occurred in either patient.

In nine patients the acute administration of procainamide or quinidine prevented initiation of torsades de pointes and any other ventricular tachyarrhythmia. In four other patients the initiation and characteristics of torsades de pointes were unaffected by the administra-

tion of procainamide (four patients) or quinidine (three patients).

Discussion

The occurrence of torsades de pointes in clinically stable patients without electrolyte disturbance or antiarrhythmic medication and normal or minimally prolonged QT_c intervals has been reported but has been infrequently emphasized.

Relationship Between Spontaneous and Induced Torsades de Pointes

The characteristics of the induced torsades de pointes were similar to those that occurred spontaneously. Although the QRS morphology and duration of individual paroxysms of torsades de pointes varied widely between consecutive episodes, in each patient the induced episodes behaved similarly to spontaneous episodes. In three patients, torsades de pointes spontaneously converted to sustained, uniform-morphology ventricular tachycardia; in each of these patients, spontaneous episodes of rapid sustained, uniform-morphology ventricular tachycardia or ventricular flutter had occurred. Furthermore, the patients in whom induced torsades de pointes progressed to ventricular fibrillation similarly had had recurrent clinical episodes of ventricular fibrillation that produced cardiac arrest.

Electrophysiologic Characteristics of Torsades de Pointes

The torsades de pointes investigated in this series met the most frequently used criteria for a reentrant arrhythmia, namely, reproducible initiation by premature stimulation.^{12, 21} In 19 of 21 patients (92%), the torsades de pointes was inducible by one or two ventricular extrastimuli. These data are in agreement with the studies of Evans et al., in which torsades de pointes was inducible by programmed electrical stimulation in four of four patients.²²

Most paroxysms of torsades de pointes terminated spontaneously. This observation does not provide data regarding the mechanism of the arrhythmia because it is compatible with either an automatic or reentrant arrhythmia. The spontaneous evolution of torsades de pointes into a uniform-morphology ventricular tachycardia, which has the typical characteristics of a reentrant ventricular tachycardia being terminated by programmed stimulation and/or cardioversion, however, does support the reentrant mechanism.

Effect of Procainamide and Quinidine

The conversion of torsades de pointes to typical sustained ventricular tachycardia by administration of either procainamide or quinidine supports the reentrant-mechanism hypothesis. The resultant ventricular tachycardias have the characteristic response to programmed stimulation generally reported in reentrant ventricular tachycardia. Similar clinical responses to procainamide have been reported.² Furthermore, cure of torsades de pointes was accomplished by resection of the site of origin of this typical ventricular tachycardia in two patients, suggesting that the torsades de pointes and the uniform-morphology ventricular tachycardia were actually different manifestations of the same arrhythmia.

Unifying Hypothesis Regarding the Mechanism of Recurrent Ventricular Tachyarrhythmias

Recurrent sustained ventricular tachycardia, a regular and sustained tachyarrhythmia, usually fulfills the clinical electrophysiologic characteristics that suggest a reentrant mechanism. Recurrent ventricular fibrillation occurring in clinically stable patients can also, in certain patients, be initiated by programmed stimulation, suggesting initiation by reentry. Although ventricular electrograms during ventricular fibrillation tend to be irregular and fractionated, local ventricular electrical activity at the onset and during ventricular fibrillation can be regular and discrete.²³ The relationship of these recurrent ventricular tachyarrhythmias is unclear; however, a better understanding of this relationship may be obtained by study of torsades de pointes, a variant type of ventricular tachycardia that has characteristics of both of these classic ventricular tachyarrhythmias.

Evans et al.²² and Fontaine et al.²⁴ presented data that support a reentrant mechanism for this arrhythmia. Evans et al. showed that torsades de pointes was inducible in four patients.²² Fontaine et al.²⁴ suggested that torsades de pointes results from a re-

entrant mechanism because their patients had prolonged ventricular refractory periods and delayed potentials recorded during normal sinus rhythm.

Our data suggest that torsades de pointes may be a variant form of sustained ventricular tachycardia. Torsades de pointes may be a rapid and, at its origin, a regular ventricular tachyarrhythmia in which the electrocardiographic irregularity is caused by variable patterns of ventricular activation caused by changing exit sites from the origin of the arrhythmia or local conduction block related to encountering refractoriness as a result of the short cycle length of the tachycardia. Moreover, torsades de pointes can spontaneously regularize into a uniform-morphology tachyarrhythmia as refractoriness decreases with the short cycle length, eliminating local block, or as ventricular activation proceeds via a single exit site as functional changes at the other exit sites preclude exit from them. Further support of this hypothesis is the observation that procainamide or quinidine, which increase the cycle length of ventricular tachycardia, frequently convert this irregular tachyarrhythmia to a ventricular tachyarrhythmia with a uniform morphology that has characteristics typical of reentrant ventricular tachycardia. The mechanism for this conversion may be a relatively greater depression of conduction than increase in refractoriness caused by procainamide or quinidine.

These observations and hypotheses are consistent with studies in experimental chronic infarction in which arrhythmias morphologically similar to torsades de pointes are caused by rapid regular ventricular tachyarrhythmias that produce variable ventricular activation patterns. Nhon et al.²⁵ showed that varying exit sites from a rapid ventricular tachycardia can produce a pattern of torsades de pointes. They suggested that varying exit sites or the course of the reentrant circuit could produce the QRS morphology that is typical of this arrhythmia. Ideker et al.²⁶ showed that the electrocardiographic pattern of torsades de pointes can also be caused by the successive summation of two to four depolarization wave fronts as they course over the epicardium from the site of origin of a rapid ventricular tachycardia.²⁶ The random and continuously varying summation of these wave fronts produces undulating cyclical QRS patterns.

Torsades de pointes, on the other hand, can also lead to ventricular fibrillation, presumably by the same mechanism by which rapid uniform-morphology ventricular tachycardia or rapid ventricular pacing produces ventricular fibrillation. Ventricular activation can become progressively chaotic as wave fronts fractionate and encounter areas of differing refractoriness and conductivity. This heterogeneous pattern of conduction and recovery can lead to the self-sustaining fibrillatory process.

Other explanations are possible. Multifocal ventricular tachycardia with fusion complexes producing the varying QRS morphologies might also explain our observations; however, we believe our hypothesis is the best explanation.

Relationship to Other Investigations

The electrocardiographic features of torsades de pointes were reported over half a century ago by MacWilliams³ and Wiggers.⁴ Schwartz et al. thoroughly described the syndrome, including the association with bradycardia and prolonged QT intervals.^{5, 27-31} They also emphasized the interrelationship between this arrhythmia and uniform-morphology ventricular tachycardia and ventricular fibrillation. Schwartz and co-workers called the arrhythmia transient ventricular fibrillation. Since their work in the 1940s, a variety of unusual forms of ventricular tachyarrhythmias have been described. They have been termed paroxysmal ventricular fibrillation,³² transient recurrent ventricular fibrillation,³³ pseudofibrillation,³ cardiac ballet,³⁴ atypical ventricular tachycardia,¹⁹ ventricular fibrillo-flutter,³⁵ polymorphous ventricular tachycardia,³⁶ multiform ventricular tachycardia³⁷ and torsades de pointes.¹ This surfeit of names suggests a paucity of data regarding the cause of this arrhythmia.

We excluded from analysis patients in whom torsades de pointes was related to transient factors, such as hypokalemia or antiarrhythmic drug therapy. Twenty of our 21 patients had chronic and stable structural heart disease, and 12 (60%) had chronic coronary artery disease. Most investigators have reported a similar incidence of organic cardiac disease. Although torsades de pointes has been reported to occur in patients with stable chronic heart disease, and particularly coronary artery disease, this etiology has not been emphasized. We cannot comment on the relative frequency of the different etiologies of torsades de pointes because we reported only patients in whom transient factors did not play a role. The patients in whom torsades de pointes is caused by transient pharmacologic or metabolic abnormalities are less stable clinically and more difficult to study. Furthermore, these patients are usually promptly treated by removing the underlying cause and diagnostic electrophysiologic catheterization is necessary less often. Our present studies, therefore, have been confined to patients in whom the arrhythmia occurred in a stable setting.

The arrhythmias in both groups, however, are morphologically similar and, in the final analysis, arrhythmias are named for their morphology rather than etiology. Although some may disagree with calling the arrhythmia we describe torsades de pointes, because QT interval prolongation was not always present, the arrhythmias in our patients met the morphologic criteria suggested by most authors.³⁷ Until further data are available, we believe greater understanding of these ventricular tachyarrhythmias will be gained by considering them in the same group of arrhythmias rather than creating many categories. Clarification of the nosographic confusion surrounding this arrhythmia is beyond the scope of the present work; however, because these arrhythmias are so similar in morphology, etiology and clinical significance, we suggest that greater uniformity in ter-

minology may allow an organized approach to investigating their mechanisms.

Our data and those of others suggest that torsades de pointes in the setting of organic heart disease is a reentrant tachyarrhythmia with electrophysiologic characteristics of both typical ventricular tachycardia and ventricular fibrillation. Further study of the anatomic and electrophysiologic substrate of these three groups of ventricular tachyarrhythmias may produce greater understanding of the causes and processes that result in sudden cardiac death.

Acknowledgment

We thank Helaine Corr for her secretarial assistance in preparing the manuscript, the nurses and technicians of the Clinical Electrophysiology Laboratory of the Hospital of the University of Pennsylvania, and Dr. John A. Kastor, Chief of the Cardiovascular Section, for his continued enthusiastic support. We particularly thank Dr. Philippe Coumel for his discussions and suggestions about the syndrome of torsades de pointes.

References

- Dessertenne F: La tachycardie ventriculaire à deux foyers opposés variables. *Arch Mal Coeur* **59**: 263, 1966
- Dessertenne F, Gourgon R, Coumel P, Fabiato A: Tachycardie ventriculaire et torsades de pointes. *Ann Cardiol Angeiol* **20**: 243, 1971
- MacWilliams JA: Some applications of physiology to medicine. II. Ventricular fibrillation and sudden death. *Br Med J* **2**: 215, 1923
- Wiggers CJ: Studies of ventricular fibrillation caused by electric shock. II. Cinematographic and electrocardiographic observations of the natural process in the dog's heart. Its inhibition by potassium and the revival of coordinated beats by calcium. *Am Heart J* **5**: 351, 1929
- Schwartz SP, Orloff J, Fox C: Transient ventricular fibrillation. I. The prefibrillatory period during established auriculoventricular dissociation with a note on the phonocardiograms obtained at such times. *Am Heart J* **37**: 21, 1949
- Pick A: Manifestation of the vulnerable phase in the human heart. *Sudden Cardiac Death*, edited by Surawicz B, Pellegrini ED, New York, Grune and Stratton, 1964, p 44
- Slama R, Motte G, Coumel P, Dessertenne F: Le syndrome "allongement de QT et syncopes par torsades de pointes." *Laval Med* **42**: 353, 1971
- Motte G, Coumel P, Abitot G, Dessertenne F, Slama R: Le syndrome QT long et syncopes par torsades de pointes. *Arch Mal Coeur* **63**: 831, 1970
- Mallion JM, Avezou F, Denis B, Yacoub M, Martin-Noel P: Syndrome de QT long avec torsades de pointes, syncopes et insuffisance coronarienne. *Arch Mal Coeur* **65**: 1209, 1971
- Brochier M, Motte M, Fauchier JP: Tachycardie ventriculaire en torsades de pointes. *Actual Cardio-vasc Medico-Chirurg* **6**: 171, 1972
- Slama R, Coumel P, Motte G, Gourgon R, Waynberger M, Touche S: Tachycardies ventriculaires et torsades de pointes: frontières morphologiques entre les dysrhythmies ventriculaires. *Arch Mal Coeur* **66**: 1401, 1973
- Krikler DM, Curry PVL: Torsades de pointes, an atypical ventricular tachycardia. *Br Heart J* **38**: 117, 1976
- Smith WM, Gallagher JJ: Les torsades de pointes. *Ann Intern Med* **93**: 578, 1980
- WHO/ISFS Task Force: Definition of terms related to cardiac rhythm. *Eur J Cardiol* **8**: 127, 1978
- Bazett HC: An analysis of the time-relations of electrocardiograms. *Heart* **7**: 353, 1920
- Simonson E, Cady LD, Woodbury M: The normal QT interval. *Am Heart J* **63**: 747, 1962
- Josephson ME, Horowitz LN, Farshidi A, Kastor JA: Recurrent sustained ventricular tachycardia: I. Mechanisms. *Circulation* **57**: 431, 1978

18. Josephson ME, Horowitz LN, Farshidi A, Spielman SR, Michelson EL, Greenspan AM: Sustained ventricular tachycardia — evidence for protected localized reentry. *Am J Cardiol* **42**: 416, 1978
19. Horowitz LN, Josephson ME, Harken AH: Ventricular resection guided by epicardial and endocardial mapping for treatment of recurrent ventricular tachycardia. *N Engl J Med* **302**: 589, 1980
20. Wellens HJJ: Electrical stimulation of the heart in the study and treatment of tachycardias. Baltimore, University Park Press, 1977, pp 14–22
21. Curry PVL: Fundamentals of arrhythmias. *In* Modern Method of Investigation in Cardiac Arrhythmias. The Modern Electrophysiologic Approach, edited by Krikler DM, Goodwin JF, London, WB Saunders Co, 1975, pp 65–76
22. Evans TR, Curry PVL, Fitchett DH, Krikler DM: "Torsades de pointes" initiated by electrical ventricular stimulation. *J Electrocardiol* **9**: 255, 1976
23. Josephson ME, Spielman SR, Greenspan AM, Horowitz LN: Mechanism of ventricular fibrillation in man. *Am J Cardiol* **44**: 623, 1979
24. Fontaine GH, Frank R, Welti JJ, Grosogeat Y: Electrophysiology of torsades de pointes. *In* Proceedings of the VI World Symposium on Cardiac Pacing, edited by Meere C. Chapter **6**: 3, 1979
25. Nhon N, Hope RR, Kabell G, Scherlag BJ, Lazzara R: Torsades de pointes: electrophysiology of atypical ventricular tachycardia. *Am J Cardiol* **45**: 494, 1980
26. Ideker RE, Harrison L, Smith WM, Kasell J, Smith WM: Epicardial mapping of the transition to ventricular fibrillation induced by acute ischemia in the dog. (abstr) *Circulation* **60** (suppl II): II-110, 1979
27. Schwartz SP: Transient ventricular fibrillation. A study of fibrillary process in man. *J Mt. Sinai Hosp* **8**: 1005, 1942
28. Schwartz SP, Pool de Sola N: Transient ventricular fibrillation. III. The effects of bodily rest, atropine sulphate and exercise on patients with transient ventricular fibrillation during established auriculo-ventricular dissociation. *Am Heart J* **39**: 361, 1950
29. Schwartz SP, Hallinger L, Swiperiellie A: Transient ventricular fibrillation. IV. The effects of procainamide on patients with transient ventricular fibrillation during established auriculo-ventricular dissociation. *Circulation* **6**: 193, 1952
30. Schwartz SP, Margolies MP, Firenzi A: Transient ventricular fibrillation. V. The effects of the oral administration of quinidine sulphate on patients with transient ventricular fibrillation during established auriculo-ventricular dissociation. *Am Heart J* **45**: 404, 1953
31. Schwartz SP, Hallinger LN: Transient ventricular fibrillation. VI. Observations on the peripheral arterial pulse pressures in the course of transient ventricular fibrillation during established auriculoventricular dissociation. *Am Heart J* **48**: 390, 1954
32. Loeb HS, Pietras RJ, Gunnar RM, Tobin JR Jr: Paroxysmal ventricular fibrillation in two patients with hypomagnesemia. Treatment by transvenous pacing. *Circulation* **37**: 210, 1968
33. Tamura K, Tamura T, Yoshida S, Inul M, Fukuhara N: Transient recurrent ventricular fibrillation due to hypopotassemia with special note on the U wave. *Jpn Heart J* **8**: 652, 1967
34. Smirk FH, Ng J: Cardiac ballet repetitions of complex electrocardiographic patterns. *Br Heart J* **31**: 426, 1969
35. Ranquin R, Parizel G: Ventricular fibrillo-flutter (torsade de pointes); an established electrocardiographic and clinical entity. *Angiology* **28**: 115, 1977
36. Sclarovsky S, Strasberg B, Lewin RF, Agmon J: Polymorphous ventricular tachycardia: clinical features and treatment. *Am J Cardiol* **44**: 339, 1979
37. Zilcher H, Glogar D, Kaindl F: Torsades de pointes: occurrence in myocardial ischemia as a separate entity. Multiform ventricular tachycardia or not? *Eur Heart J* **1**: 63, 1980